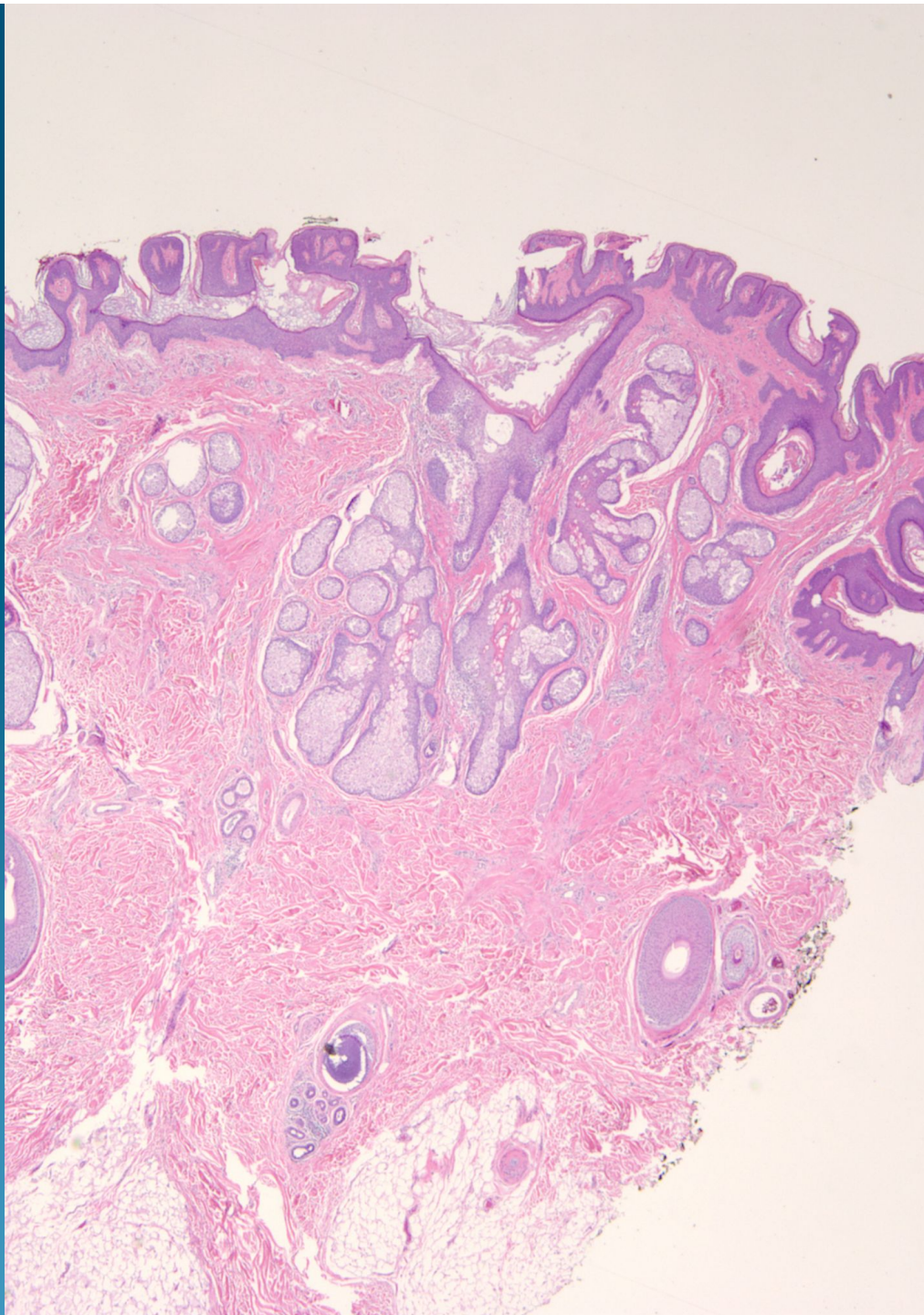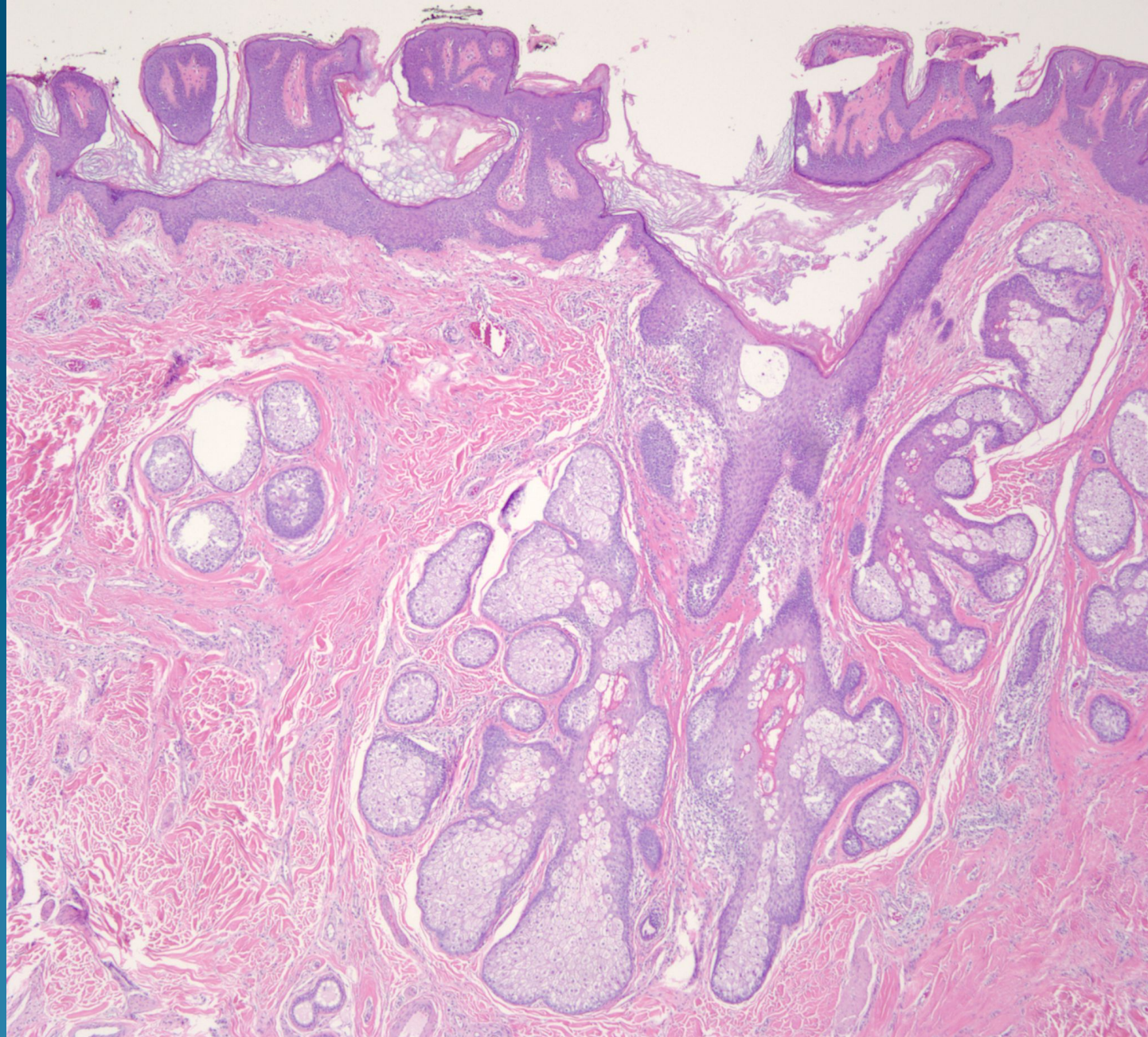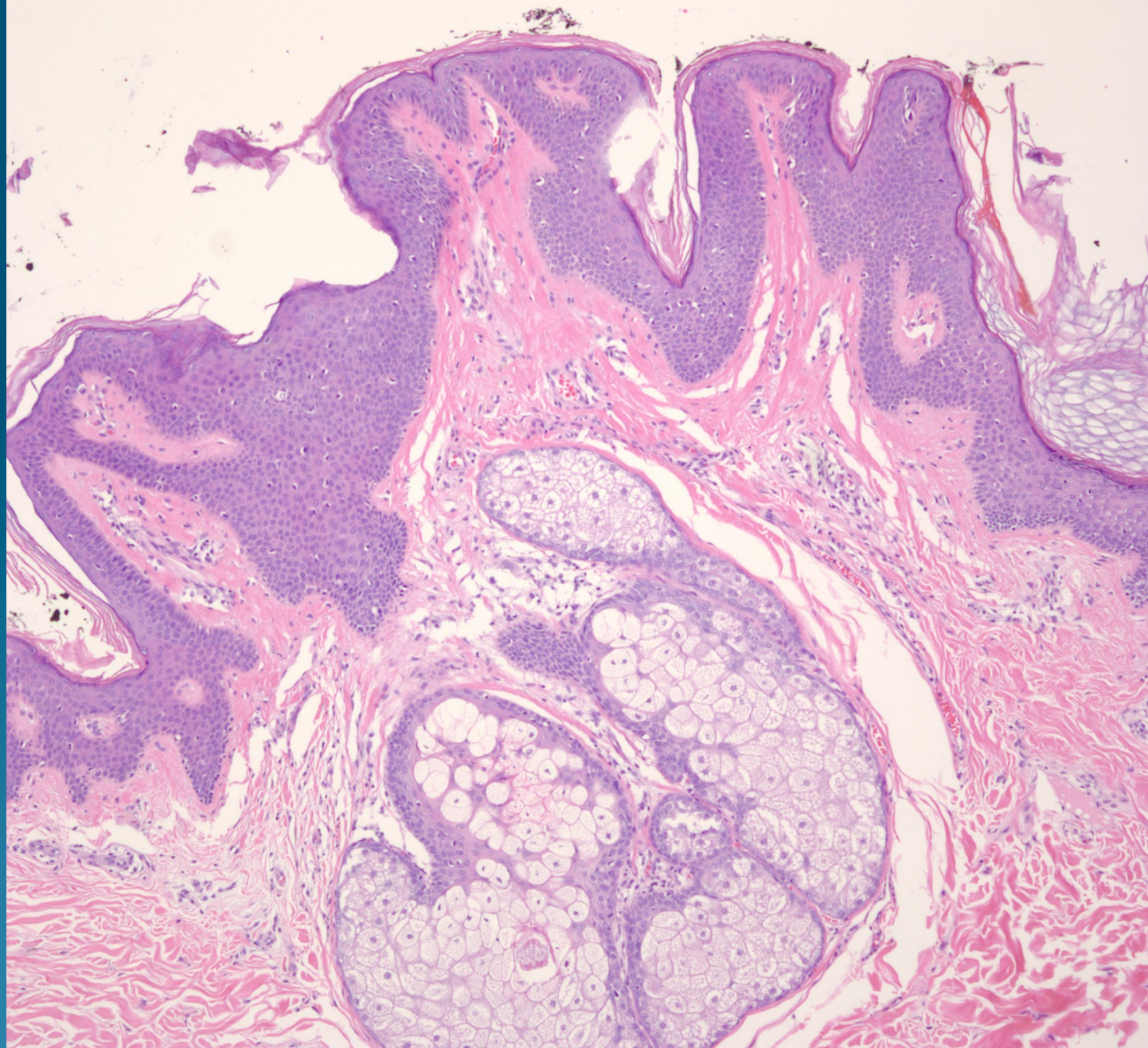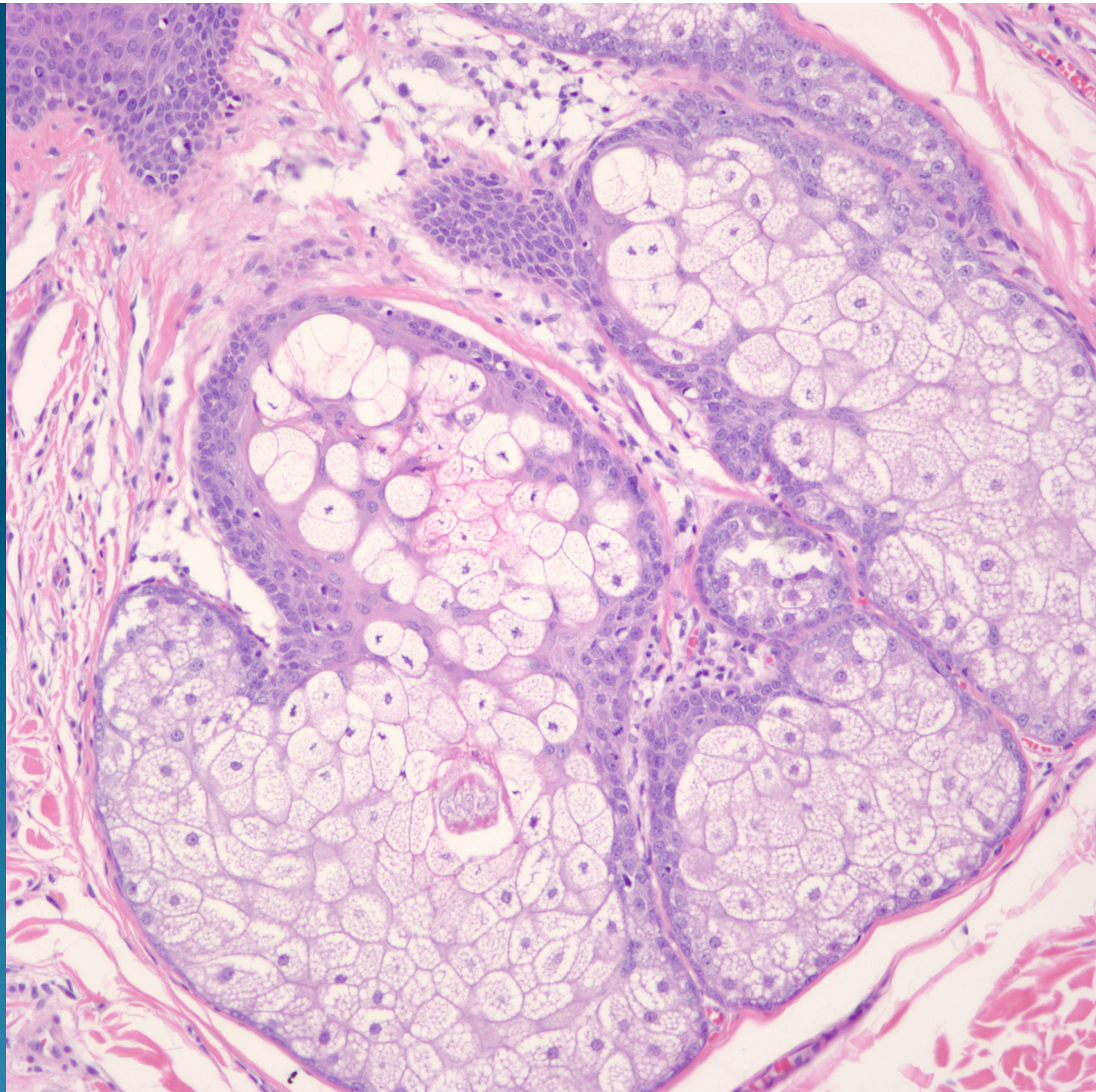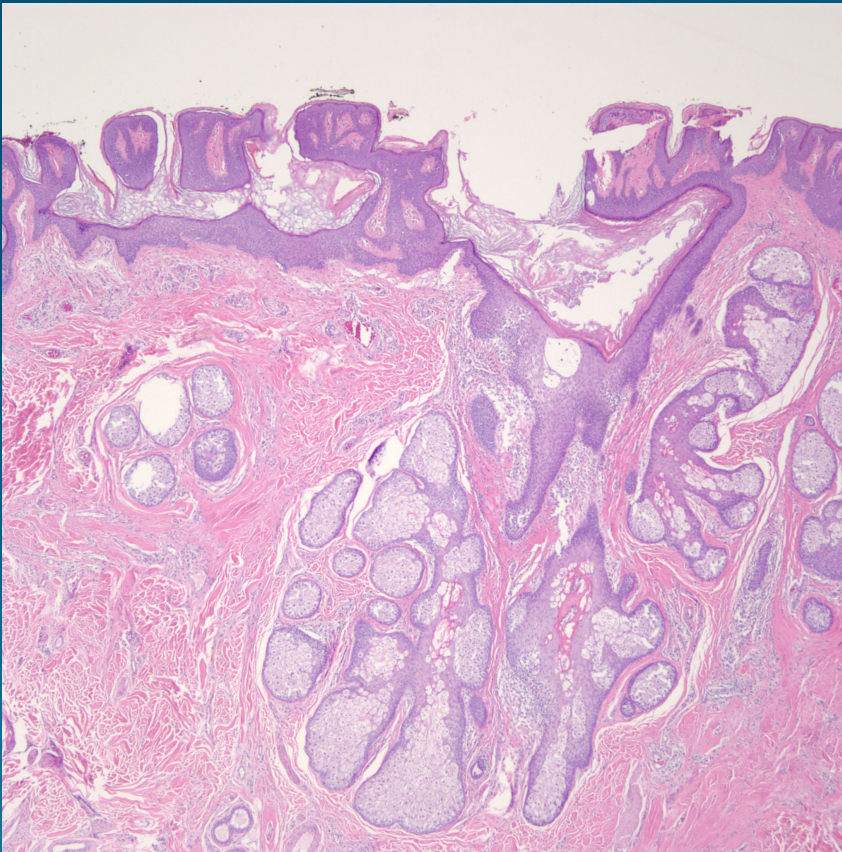


# Nevus Sebaceus



# Pearls



- Note spelling “sebaceous” NOT “sebaceous”
- Variable epidermal hyperplasia with papillomatosis
- Hyperplastic sebaceous glands juxtaposed to epidermis
- Look carefully to exclude a concomitant malignancy.